

## TREATMENT OF PERIORAL RHYTIDES WITH VOLTAIC ARC DERMOABRASION

A. SCARANO<sup>1</sup>, D. D'ANDRIA<sup>1</sup>, G. FIPPI<sup>1</sup>, F. DI CARLO<sup>1</sup>  
F. CARINCI<sup>2</sup>, D. LAURITANO<sup>3</sup>

<sup>1</sup>*Department of Oral Science, Nano and Biotechnology University of Chieti-Pescara*

<sup>2</sup>*Department of D.M.C.C.C., Section of Maxillofacial and Plastic Surgery, University of Ferrara, Ferrara, Italy*

<sup>3</sup>*Department of Neurosciences and Biomedical Technologies, Dental Clinic,  
University Milano Bicocca, Milan, Italy*

Perioral rhytids can be successfully treated with various methods, including dermabrasion, carbon dioxide laser, filler and chemical peels. Ablative resurfacing is typically used to treat rhytides, dyschromia, and scarring. A novel electrosurgical technology was used in this study for treatment of perioral rhytides. The authors treated 15 patients (11 female and 4 male) for perioral rhytides with Voltaic arc dermoabrasion technique. Patient ages ranged between 30 and 65 years and the majority (90%) of these perioral areas had class II and III wrinkle scores. Voltaic arc dermoabrasion (PLEXR, GMV s.r.l. Grottaferrata, Italy) were used to remove the keratinized layer for point perioral area. Treatment is minimally painful and in the authors' experience require no anesthesia. No discomfort should be expected once the voltaic arc dermoabrasion treatment is concluded. The perioral dermis appears as a pale, erythematous, dull surface. Bleeding is not seen unless excessive abrading occurs with the saline-moistened gauze. No hyperpigmentation, hypopigmentation, erythema, ecchymosis, pain, itching, outbreaks of herpes, infectious processes and scarring was observed. In conclusion fine rhytides, particularly in the perioral areas may be completely eradicated with voltaic arc resurfacing; deeper creases are also improved, probably secondary to a general tightening effect.

Increased skin laxity, along with habitual repeated contraction of the underlying facial muscles, results in wrinkles or rhytids. In general, the aging process of the face is a progressing toward atrophy. Biochemically, the ratio of type I to type III collagen is reduced and the elastic fibers, spread in laminar shape between the collagen bundles, become tiny and fragmented, involving an overall reduction of the total amount of collagen. In addition to ageing, environmental damaging agents such as actinic radiations may accelerate this decline. Treatment of perioral rhytids is a procedure commonly requested by patients who are typically over 50 years and smoke, or are former smokers. Perioral rhytids can be successfully treated with various methods, including dermabrasion, carbon dioxide laser, filler and chemical peels. Ablative resurfacing is typically used to treat rhytides, dyschromia and scarring

(1). Dermabrasion has along history of success in the treatment of wrinkles and scars. It has recently fallen out of favor because many surgeons have found carbon dioxide lasers to be more predictable as to the depth of tissue injury (2). Advantages of dermabrasion include the relatively low cost of equipment. Disadvantages include potential exposure of health care personnel to blood-borne pathogens aerosolized by the dermabrading fraise. Mechanical facial resurfacing traces its origins from the early 20th century with the advent of dermabrasion, first described by Kronmayer in 1905 (3). Contemporary techniques include the use of a wire brush or diamond fraise, with erythema variably persisting for 7–10 days. Dermabrasion produces aerosolized particles that remain airborne for hours after the procedure and may lead to transmission of live virus (4). High-energy, short-pulsed resurfacing lasers

*Key words: Perioral rhytids, dermoabrasion, electrosurgery, skin lesions, Voltaic arc dermoabrasion.*

*Corresponding author:* Prof. Francesco Carinci, M.D  
Department of D.M.C.C.C.  
Section of Maxillofacial and Plastic Surgery  
University of Ferrara  
Corso Giovecca 203 44100 Ferrara Italy  
E-mail: [cre@unife.it](mailto:cre@unife.it) Web: [www.carinci.org](http://www.carinci.org)  
Phone: +39.0532.455874 Fax: +39.0532.455876

25 (S2)

0393-974X (2012)  
Copyright © by BIOLIFE, s.a.s.  
This publication and/or article is for individual use only and may not be further reproduced without written permission from the copyright holder.  
Unauthorized reproduction may result in financial and other penalties

are costly necessitate protection from beam hazards, and, as with other resurfacing modalities, may be associated with persistent erythema, hypopigmentation and hyperpigmentation, hypertrophic scarring (5). Traditional electrosurgery uses highradiofrequency (RF) energy that generates heat (400°C-600°C) that abruptly vaporizes intracellular and extracellular fluids, causing tissue desiccation. Cutaneous resurfacing with the use of traditional RF devices has been reported, albeit rarely. The electrosurgical equipments do not take in consideration the different tissues conductivity. It is good conductors as vascular tissue or hydrated skin are easy to treat with electro-surgery. To handle this problems it is studied a voltaic arc dermoabrasion. The voltaic arc acts without getting in tip-tissue contact, creating a gentle coagulation. There is no electric passage zone, for this reason the dermoabrasion it is not influenced from the tissue electric resistance (6). A novel electrosurgical technology was used in this study for treatment of perioral rhytides.

#### MATERIALS AND METHODS

The authors treated 15 patients (11 female and 4 male) for perioral rhytides with voltaic arc dermoabrasion technique. Patient ages ranged between 30 and 65 years and the majority (90%) of these perioral areas had class II and III wrinkle scores. Patients of any age and in good health are candidates for laser resurfacing. The optimal candidate is a patient with Fitzpatrick skin types I to III with photodamage and moderate postoperative expectations. Contraindications to the procedure include a history of keloids or connective tissue diseases. Dermatologic conditions which result in a reduction in adnexal structures, such as history of radiation therapy or scleroderma, should also serve as contraindications because of the absence of stem cells in the appendageal bulge, which reduces re-epithelialization postoperatively. After have read the brochure and discussed risks and benefits and alternatives of face rejuvenation, and after having all of their questions satisfactorily answered, each patient signed the informed consent form, describing the possible complications and untoward effects such as: bruising, swelling. Voltaic arc dermoabrasion (PLEXR, GMV s.r.l. Grottaferrata, Italy) (Fig.1) was used to remove the keratinized layer for point perioral area. Treatment is minimally painful and in the author's experience require no anesthesia. No discomfort should be expected once the Voltaic arc dermoabrasion treatment is concluded (Fig. 2). Voltaic arc dermoabrasion technique for rhytides, a first "pass" of non overlapping and vaporizing voltaic arc, is performed, followed by gentle yet thorough wiping of the desiccated debris with saline-soaked sponges. The perioral skin surface then reveals a pink hue, representing partially denatured papillary dermis. No further special instructions are needed, and the patients go back to work immediately. The results were evaluated one month after the treatment.

To evaluate the results, by means of a joined investigator was based on clinical observation and comparison of pretreatment and post treatment photographs of the areas of interest at each

follow-up visit.

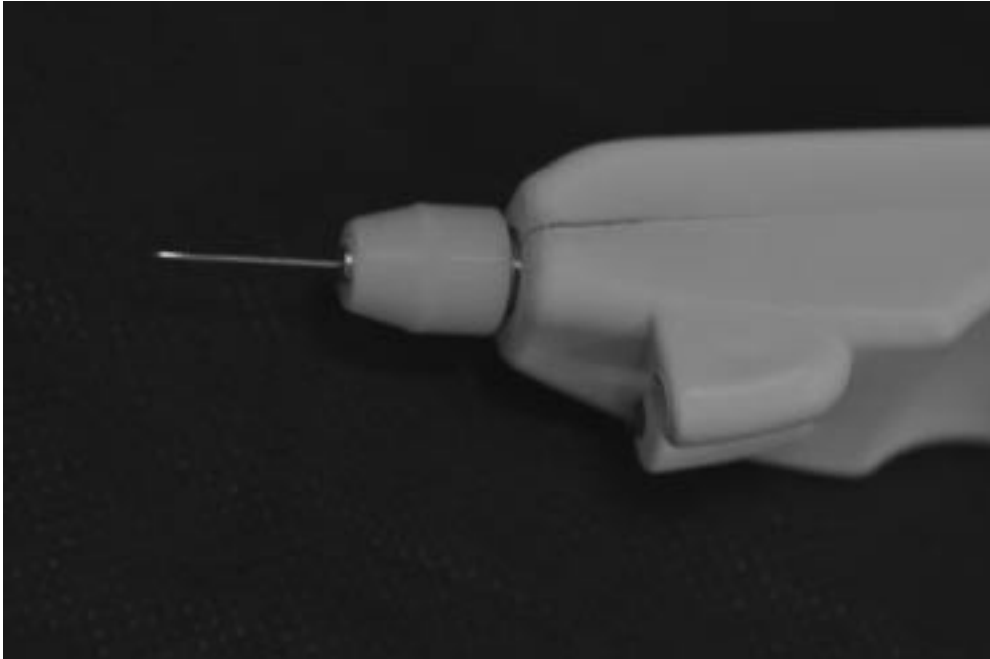
#### RESULTS

The perioral dermis appears as a pale, erythematous, dull surface. Bleeding is not seen unless excessive abrading occurs with the saline-moistened gauze. Subsequent passes produce a transient blanch lasting only about 10 to 15 seconds (Fig. 3). Careful attention must be given to the path of the wand to ensure even treatment. No dermal contraction is seen during treatment. During the first postoperative week, 9 patient's areas exhibited edema, while edema was present in 7 patients of treated areas at the day 30 follow-up examination. The results were evaluated one month after the treatment. Marked improvement was seen in nine of the 15 patients, in whom 50-75% of rhytides class I-II were improved (fine lines and generalized deep lines with moderate textural changes). Moderate improvement was seen in five of 15 patients, in whom 25-50% of class I-II rhytides were improved. No hyperpigmentation, hypopigmentation, erythema, ecchymosis, pain, itching, outbreaks of herpes, infectious processes and scarring was observed (Fig.4).

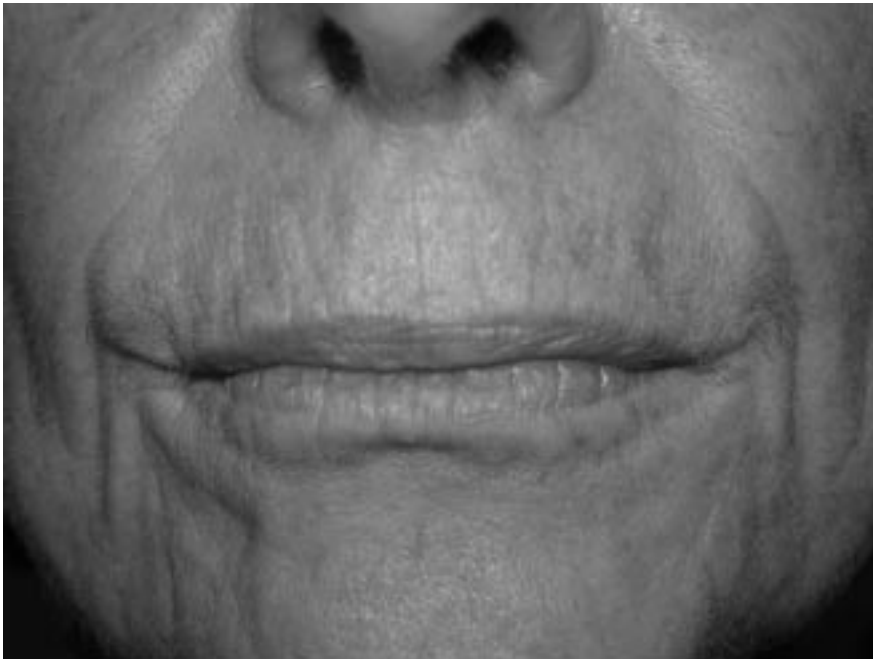#### DISCUSSION

Electrosurgery is the application of an alternative electric current with a high voltage on a biological tissue with a thermal effect to achieve an incision or coagulation.

The electrosurgery is one of the most soft surgery technique used for tissues, which may be ablated leaving a 100-400µm necrotic tissue layer. It is a surgical technique that uses high frequency (HF) electric current to realize a simple and easy cut or /and clot. So it is possible to have a precise cut and clotting at the same moment having a free blood operative field (7). The electrosurgical equipments do not take in consideration the different tissues conductivity. There are good conductors such as vascular tissue or hydrated skin, so, easy to treat with electrosurgery. To handle this problems it is studied a voltaic arc dermoabrasion. The voltaic arc acts without getting in tip-tissue contact, creating a gentle coagulation. There is no electric passage zone, for this reason the dermoabrasion it is not influenced from the tissue electric resistance. During operation it is important to be protected with masks to avoid viral particles inhalation (8). Skin resurfacing by the cosmetic surgeon is a process that causes a controlled injury to skin and then stimulates a wound healing response. In response to injury, fibroblasts in the papillary dermis increase production of type I and type III procollagen in addition to transforming growth factor beta-1. The collagen increase in turns thickens the



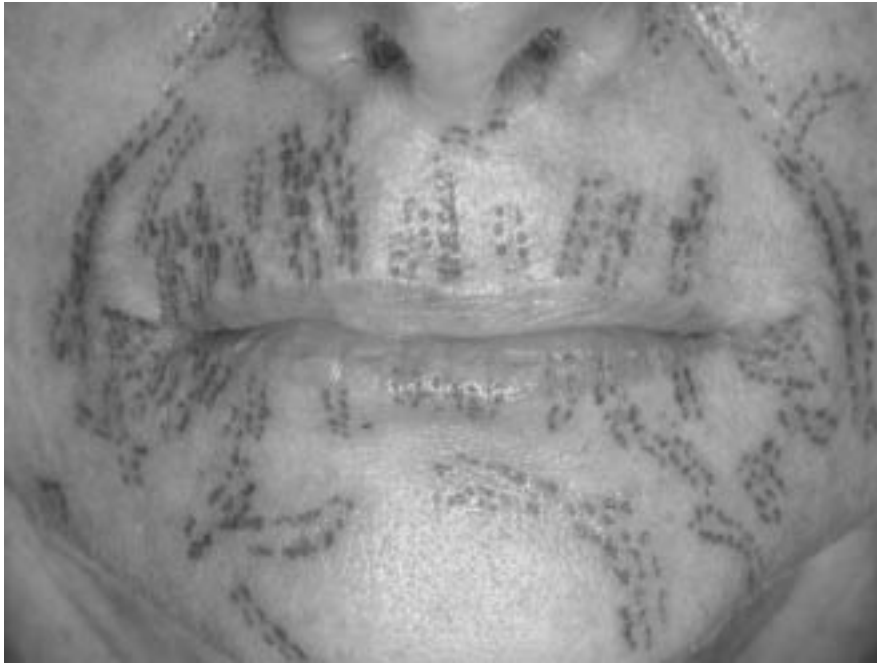**Fig. 1.** *Voltaic arc dermabrasion unit.*



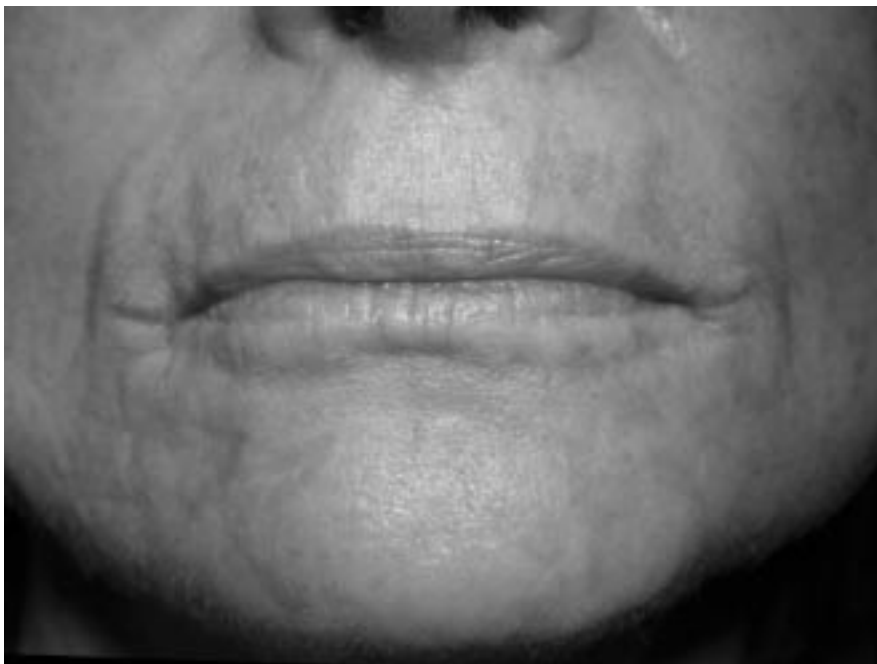**Fig. 2.** *Before treatment of perioral rhytids.*

dermis, which enhances the tensile strength of the skin and yields the clinical appearance of rejuvenation. Ablative resurfacing achieves the outcome of rejuvenation by the destruction of the outermost and thus most photodamaged layers of the skin. The subsequent laying down of newly

formed collagen and a tightened skin appearance follows this removal. Voltaic arc dermoabrasion technique is a new technique for skin resurfacing (9). It can yield excellent results when a well-trained surgeon performs the procedure for the appropriate patient. The keys to performing



**Fig. 3.** Appearance of a typical patient immediately after undergoing to dermabrasion with voltaic arc technique.



**Fig. 4.** Postoperative photograph of a patient after 1 month treatment resulted in a better cosmetic outcome

electro-dermabrasion are experience and understanding of its principles to provide sufficient resurfacing to the appropriate depth and minimize scar formation. Careful patient screening is crucial to ensure realistic expectations.

With meticulous postoperative care, the results can be highly satisfying for patients. Voltaic arc dermoabrasion technique resurfacing was found to be effective and safe in the treatment of perioral wrinkles in patients with skin

types I, II, and III. For the most part, healing was rapid, pain was minimal, erythema resolved within 20-30 days, and untoward effects were relatively few and short-lived. The advantage of voltaic arc dermoabrasion technique is that postoperative care is unnecessary (10). Immediately postoperatively, minimal edema resolves within several hours. The majority of patients can apply makeup and return to normal daily life immediately following treatment. A novel device for performing ablative resurfacing has been developed which works by passing of voltaic arc. The "voltaic arc" causes rapid heating of the skin with limited tissue ablation and minimal collateral thermal damage. A few reports indicate improvement in facial rhytides and scars following treatment. Epidermal regeneration occurs by 7 days postoperatively with neocollagenesis visible on histologic analysis at 30 days (11). In conclusion fine rhytides, particularly in the perioral areas may be completely eradicated with voltaic arc resurfacing; deeper creases are also improved, probably secondary to a general tightening effect.

#### REFERENCES

1. Maloney BP. Aesthetic surgery of the lip. In: Papel ID (ed). Facial plastic and reconstructive surgery. New York: Thieme Medical, 2002:344-352.
2. Prignano F, Bonciani D, Campolmi P, Cannarozzo G, Bonan P, Lotti T. A study of fractional CO<sub>2</sub> laser resurfacing: the best fluences through a clinical, histological, and ultrastructural evaluation. *Journal of cosmetic dermatology*;10:210-216.
3. Kromayer E. Rotations in strumente ein neues technisches Verfahren in der dermatologischen Kleinchirurgie. *Chir Dermatol Ztschr* 1905;12:26-28.
4. Wentzell JM, Robinson JK, Wentzell JM, Jr., Schwartz DE, Carlson SE. Physical properties of aerosols produced by dermoabrasion. *Archives of dermatology* 1989;125:1637-1643.
5. Brody HJ. Complications of chemical peeling. *The Journal of dermatologic surgery and oncology* 1989;15:1010-1019.
6. Scarano A, Bertuzzi GL, Brandimarte B. L'elettrochirurgia di lesioni cutanee: uno studio sperimentale comparativo radiobisturi vs dermoabrasore ad arco voltaico. *Esperienze dermatologiche* in press.
7. Hainer BL. Fundamentals of electrosurgery. *The Journal of the American Board of Family Practice / American Board of Family Practice* 1991;4:419-426.
8. Sawchuk WS, Weber PJ, Lowy DR, Dzubow LM. Infectious papillomavirus in the vapor of warts treated with carbon dioxide laser or electrocoagulation: detection and protection. *Journal of the American Academy of Dermatology* 1989;21:41-49.
9. Scarano A, Sinjari B, Artese L, Fippi G, Carinci F. Skin lesions induced from the radiosurgical unit and voltaic arc dermoabrasion: a rabbit model. *Int J Immunopathol Pharmacol* (in press).
10. Scarano A, Bertuzzi GL, Brandimarte B, Carinci F. Treatment of xanthelasma palpebrarum with voltaic arc dermoabrasion. *Int J Immunopathol Pharmacol* (in press).
11. Sarradet MD, Hussain M, Goldberg DJ. Electrosurgical resurfacing: a clinical, histologic, and electron microscopic evaluation. *Lasers in surgery and medicine* 2003;32:111-114.

